

OPEN ACCESS

*CORRESPONDENCE

Ikpesu Thomas Ohwofasa

Works Cited

Ikpesu Thomas Ohwofasa (2024). Automobile Cleaners and Aquatic Resources with to Oxidative Stress and Liver Histopathology in Surfactant-Exposed Fish. *Journal of Current Research and Studies*, 16-26.

*COPYRIGHT

© 2024 Ikpesu Thomas Ohwofasa.

This is an open-access article distributed under the terms of the [Creative Commons Attribution License \(CC BY\)](https://creativecommons.org/licenses/by/4.0/). The use, distribution or reproduction in other forums is permitted, provided the original author(s) and the copyright owner(s) are credited and that the original publication in this journal is cited, in accordance with accepted academic practice. No use, distribution or reproduction is permitted which does not comply with these terms

Automobile Cleaners and Aquatic Resources with to Oxidative Stress and Liver Histopathology in Surfactant-Exposed Fish

Ikpesu Thomas Ohwofasa

¹Ecotoxicology and Environmental Forensic Unit, Department of Biology, Federal University Otuoke, **Nigeria**

<https://orcid.org/0000-0002-0669-9727>

Abstract

The Ami River's fish diversity was investigated using monthly samples collected from January 2020 to August 2021. The local community, industry, and fisheries all use the river's water. The findings of the current inquiry show that there are 8 fish species that are members of 6 orders, 5 families, and 8 genera. In all sites where species were collected, the family Cyprinidae (42%), one order cypriniformes was the most prevalent 3 genera and each genera have one species *Catla catla*, *Labeo rohita*, and *Chela atpar*. Second most prevalent family-siluride (21%), order-siluriformes have two genera they have two genera each genera have one species *Wallago attu* and *Ompaok bimaculatus*. Although they were present, the number of order-siluiformes and family-Sisoridae (6%), species-*Bagarius bagarius*, have lowest distribution, Clariidae (16%) order-siluriformes- *Clariaus batracus*, and Channidae (15%), order-anabantiformes, *Channa punctatus*, was quite low at all sites. Richness range 0.20 to 0.73, abundance range between 0.25 to 0.6, evenness range 0.01 to 0.02, Shannon-Weiner index (H') range 0.01 to 0.14, Simpson index of dominance (D), range 0.01 to 0.02, Simpson index of diversity (1-D), range 0.005 to 0.06, and Simpson's reciprocal index (1/D), range 0.01 to 0.08. Reported data of all the three sites are also indicate low diversity, richness, and evenness of fish's diversity as it classifies as low diversity. The dominance index also indicates low category in Ami River.

Keywords

Sodium Dodecyl Sulfate, *Clarias gariepinus*, Reduced glutathione, Peroxidase, Liver, Markers

1. Introduction

Worldwide, industries dump millions of metric tons of heavy metals, and 80 percent of municipal wastewater is deposited directly into waterways without being purified. Water pollution from things like solvent runoff, toxic sludge, and other sources [1]. These pollutants pose a significant risk to "aquatic habitats," "human health," and "productive activities [2]

Urban streams are one of the ecosystems worst impacted by human activities [3]. Agricultural, industrial, and household wastewater nearly invariably includes untreated organic and inorganic contaminants such solvents, oils, heavy metals, pesticides, fertilizers, and suspended particles. Fish exposed to these toxins in the water may develop a range of ailments and undergo physical changes [4]

The release of these toxins into surface water bodies not only harms aquatic ecosystems, but also limits the supply of water for human consumption, industry, agriculture, and leisure. Surface water contamination from untreated car wash water has been observed in developing nations like Ghana, India, Pakistan, and Zimbabwe [7,8,9,10]. In keeping with these findings, studies suggest that only 8% of industrial and municipal wastewater is treated in low-income nations [11]. Most car wash effluent is greasy, oily, and highly turbid due to contaminants washed down from the vehicle's body [12]

Accumulation of oil and grease in bodies of water is problematic because it blocks sunlight and inhibits photosynthesis [13]. Increases in BOD, COD, temperature, and pH caused by oil and grease can degrade aquatic habitats, reduce productivity, and reduce biodiversity [14]. Dissolved and suspended solids in wastewater can be attributed in part to dirt and debris that has been rinsed off of cars. Suspended particles can make life difficult for aquatic organisms by raising biological oxygen demand (BOD), turbidity, reducing habitat, and blocking fish and macroinvertebrate gills [15]. Heavy metals have also been connected to car tires, exhausts, and fluid leakages, where they are washed out into the environment [16]

Ephemeroptera, Plecoptera, and Trichoptera (EPT) insects are among the most vulnerable to the harmful effects of pollution from metals. The usage of detergents, which increase the concentration of phosphate in water, can lead to eutrophication [17]

The majority of vehicle wash facilities in developing countries are constructed along rivers and streams for both water supply and for the disposal of vehicle wash wastewater, and this is despite the fact that the number of vehicles on the road is rising alongside urbanization and the world's population [18]. The same is true with laundry and bath detergents; their usage is a major source of pollution in waterways. Synthetic agents are a major environmental risk in densely populated cities.

In addition to being the most common species of clariid, catfish in Africa is prolific and widely distributed [19]. *Clarias gariepinus* is also endemic to parts of Asia, including Israel, Syria, and the southern part of Turkey. It's ideal for cultivation in areas with limited water supply [20], since it's a robust fish that can be supplied abundantly in waters with low oxygen levels. *C. gariepinus* is the freshwater species with the widest

latitudinal distribution on Earth, and many researchers have used it as a laboratory fish model for studying microbiological, pathogenic, or environmental research²³ due to its ability to breathe air, high fertility, quick growth rate, resilience to disease, and excellent feed conversion efficiency [21]

Sodium dodecyl sulphate is one of the primary surfactant components in shampoos and other personal care products, making pond-reared African catfish especially vulnerable to detergent exposure [22, 23,24,25]. According to Hosseini [26], sodium dodecyl sulphate ($C_{12}H_{25}OSO_3Na$) consists of a hydrocarbon chain (C_{12}) and a sulphate group affixed to the chain. It is crucial to the foaming action of conditioners and car-wash soaps [28, 29]. Considering these attributes of this surfactant we decided to examine the effects of sublethal doses of sodium dodecyl sulphate exposure on *C. gariepinus* by monitoring pathological and clinical liver changes.

2. Materials and Methods

All required protocols were followed during the fish experiments. The *C. gariepinus* used in this study were monitored from the time they were eggs until they achieved the desired maturity level. This fish was picked because it can develop quickly, is resistant to low oxygen levels and poor water quality, consumes only plant matter, and has an insatiable hunger. Their health, rate of development, absence of parasites, and absence of disease were assessed at regular intervals. The pond was drained and refilled regularly to ensure the highest possible water quality.

In April and May of 2022, the fish were spawned in a shallow pond where we supplied one male for every five females, and we kept our aquarium water at ambient temperature, pH, and conductivity levels. Breeding stocks were given a diet rich in proteins and vitamins and kept at an appropriate temperature range of 25-29°C, with daily light of 12-14 h provided by a 100-W fluorescent lamp positioned 50 cm above the water surf.

Secondary sex traits were used to categorize adults of legal age. Form and coloring of the body are examples of such distinguishing features. Males are often bigger and more imposing than females. In preparation for mating, males lose weight, bulk up with more muscle in their heads, and turn a blue-black color. Women have wider shoulders and hips than their heads, as seen from above. Their bellies soften and swell as the

spawning season approaches. Their traditional grayish-to-olive coloration persists.

Growth hormone and gonadotropin hormone, both produced by the pituitary gland, were utilized as a catalyst and inciting agents in this fish breeding experiment. The location of this gland is underneath the brain. Carefully removing the pituitary gland from the fish, preserving it in alcohol, drying it on filter paper, and then grinding it in a mortar. When the time and place were right, the pituitary gland powder would be mixed with a tiny bit of distilled water and injected. All of it is injected, and women get twice as much as men. The initial injection typically accounts for 10%-20% of the entire dose. At the second injection for the female, a single shot is given to the males. Fish injected in the evening started reproducing at night. Each injection is given twice daily, once in the morning and again six hours later. The pectoral fin or pelvic fin was used as a point of entry for the intraperitoneal injection.

The young fish were injected, and then transferred to breeding tanks right away. One female and two males make up a typical mating pair. After the young fish are released, the water flow in the spawning tank is kept at a low, steady rate. The average time for spawning to happen after the second injection is between four and six hours. The female lays eggs, which the male then fertilizes with his milt.

Fish eggs take 18 hours to hatch, and their filthy yellow coloration distinguishes them from the white of unfertilized eggs. A fertilized egg may be identified by the presence of a hanging yolk sac, from which the embryo will take nutrients over the next few days. At temperatures of 28–31 degrees Celsius, hatching takes four days, while it takes five days at temperatures of 20–22 degrees Celsius. Fry emerge from the hatchling's yolk sac after it has been digested. Fry can find their own food, take on the appearance of fish, and mature to a length of 1-2 cm all on their own. A fry is called a fingerling when it is between 5 and 10 centimeters long. Fry mature into fingerling size in 45-60 days. Formulated diets of soy powder or finely powdered cake and rice bran were fed to the fry and fingerlings four to five times daily. The nursery pond is emptied and the fry are moved to the raising pond after two to three weeks.

The greenhouse was constantly cleaned to mimic the fish's natural environment. Fifteen earthen ponds, each measuring 27 1/4 by 24 1/8 by 29 1/2 inches, and holding 60 gallons of water, were constructed out of

clayey loam soil. After 12 weeks of being fed a powdered cake and rice bran three times a day, ten fingerlings were placed in each of the final ponds. Aquariums were emptied twice weekly and cleaned with a manual pumping apparatus to remove old water before receiving fresh distilled water. After the 12th week, there was no sign of mortality.

2.1 Analytical

After 12 weeks, the final ponds and their repetitions were given 30 days of exposure to field-observed SDS concentrations (0.05, 0.10, 0.15, and 0.20) g/L and the control. Throughout the study, both groups of fish received twice-daily meals equal to about 3% of their body weight. The water and poisons in the clay ponds were replaced daily, and they were kept as clean as possible. The physicochemical parameters of the water used in the experiment were monitored continuously. Laboratory evaluation of biochemical and histological profiles occurred on days 2, 16, and 30. A fish is selected from each pond at the conclusion of each trial period, then swiftly anesthetized with MS222 (Ethyl 3-aminobenzoate methanesulfonate salt, Sigma) in a well-ventilated container on arrival at the lab.

Following the methods outlined by Congleton and LaVoie [30], blood was collected from the caudal vein of each fish, which is located behind the spine. This blood was collected and centrifuged in tubes that did not contain any anticoagulants. In order to separate the serum from the blood, it was centrifuged at 3,000 RPM for 10 minutes. We then refrigerated the serum at 80 degrees until analysis. Liver, kidney, and gills were removed from the fish, frozen in liquid nitrogen, and stored at -25°C until analysis; the liver was later fixed in 10% phosphate-buffered formalin for histology. During the study periods, there were no deaths in any of the groups. We dumped the unused fish back into the main pond.

2.2 Reduced Glutathione Determination

Thiol-containing tripeptide (-glutamyl-cysteinylglycine), reduced glutathione, is a powerful antioxidant in many organisms. It has been associated with sulfhydryl group oxidation state maintenance in proteins and xenobiotic detoxification and clearance. Some human diseases, such as cancer and cardiovascular disease, involve GSH in their pathogenesis. Glutathione is present in cells in both its reduced (GSH) and oxidized (GSSG) forms under normal physiological conditions, with GSH being the more prevalent.

Reduced glutathione levels were determined using an assay kit purchased from Sigma Aldrich (located at 3050 Spruce Street, St. Louis, Missouri 63103, USA). After centrifuging at 12000 rpm for 15 minutes, we incubated the mixture at 4 °C for an hour to allow the sulphosalicylic acid to fully dissolve in the serum. The supernatant was adjusted to a pH of 7.4 by adding 2.6 ml of a potassium phosphate buffer (0.1 M). After adding 0.2 mL of 5, 5'-dithiobis-2-nitrobenzoic acid (DTNB), the absorbance at 412 nm was measured.

2.3 Assessment of Lipid Peroxidation

The Olagoke [31] method was used to determine total malondialdehyde (MDA), an indicator of lipid peroxidation. A 1: 1: 1 ratio of supernatant to TCA-TBA HCL reagent was used. 0.37 percent thiobarbituric acid, 0.24 percent hydrochloric acid, and 15 percent thiocetic acid. a reagent composed of tricarboxylic acid, thioarbituric acid, and hydrochloric acid, heated to 100 degrees Celsius for 15 minutes. Centrifugation at 3000 rpm for 10 minutes extracted the flocculent components. The absorbance at 532 nm was measured against a blank after the supernatant was discarded. The MDATBA- complex's molar extinction value was used to determine MDA, which was determined to be 1.56105M/Cm.

2.4 Histomorphology Examination

Histological analysis was performed using the method described by Gewaily and Abumandour30. Cut into 0.5 cm³ chunks, the tissue samples were then fixed in 10% neutral buffered formaldehyde for 24 hours. Paraffin wax was then poured over the samples after they had been dried in various strengths of alcohol. Hematoxylin and eosin were used to stain the sections after they were cut to a thickness of 5 m using a Leica rotatory microtome (RM 20352035; Leica Microsystems, Wetzlar, Germany). The tissue sections were examined

using a BX50/BXFLA microscope (Olympus, Tokyo, Japan).

2.5 Statistical Analysis

Data were analyzed using Minitab, SAS (SAS Institute Inc., 1985), SPSS (SPSS Inc., Chicago, Illinois, USA), Microsoft Excel (Microsoft Corporation, Roselle, Illinois, USA), and SPSS (SPSS Inc., 2016). The least significant difference (LSD) between the experimental and control groups was evaluated using post hoc testing at a 0.05 and 0.01% significance level, respectively.

3. Results

There was a consistent downward trend in the GSH levels of the liver, gills, and kidneys across all SDS concentrations throughout the exposure period. Percentage decline shows that enzyme inhibition is greatest in the liver (36%), followed by the kidney (27%) and the gills (23%). The enzyme's activity in all three organs did not significantly alter on day 2 ($p > 0.05$) in response to the exposure concentrations tested (Table 1).

Gill and renal variation were not significant ($p > 0.05$) over time. At higher doses and exposure lengths, liver activity was extremely significant ($p < 0.05$, $p < 0.01$) (table 1). On days 2 to 30, GSH activity in nmol GSH/g tissue varies from 2.86 ± 0.02 to 1.64 ± 0.20 in the liver, 1.90 ± 0.03 to 1.83 ± 0.20 in the kidney, and 1.62 ± 0.12 to 1.56 ± 0.03 in the gills at 0.05 mg/L SDS. At 0.10mg/L, 0.15mg/L, and 0.20mg/L SDS, liver variations were 2.82 ± 0.05 to 1.60 ± 0.02 , 2.80 ± 0.30 to 1.49 ± 0.26 , and 2.80 ± 0.18 to 1.34 ± 0.13 . 1.78 ± 0.04 to 1.64 ± 0.30 , 1.59 ± 0.01 to 1.32 ± 0.10 , 1.54 ± 0.01 to 1.26 ± 0.50 were the renal variations. In the gills, the variations at 0.10mg/l, 0.15mg/l, and 0.20mg/l SDS were 1.58 ± 0.10 to 1.52 ± 0.01 , 1.52 ± 0.23 to 1.42 ± 0.03 , and 1.50 ± 0.03 to 1.37 ± 0.04 .

Table 1: GSH Activities (nmol GSH/g Tissue) In the Tissues of C. Garie Pinus Induced with Subacute of Surfactant Sodium Dodecyl Sulfate. Data Are Expressed as Mean \pm Standard Error

Concentrations (mg/L)		0.00	0.05	0.10	0.15	0.20
Duration (Days)	Tissues	Mean \pm SE	Mean \pm SE	Mean \pm SE	Mean \pm SE	Mean \pm SE
2	Liver	3.20 ± 0.03^a	2.86 ± 0.02^a	2.82 ± 0.05^a	2.80 ± 0.30^a	2.80 ± 0.18^a
	Gills	1.69 ± 0.13^a	1.62 ± 0.12^a	1.58 ± 0.10^a	1.52 ± 0.23^a	1.50 ± 0.03^a
	Kidney	2.13 ± 0.01^a	1.90 ± 0.30^a	1.78 ± 0.04^a	1.59 ± 0.01^a	1.54 ± 0.01^a
30	Liver	3.20 ± 0.25^a	1.64 ± 0.20^a	1.60 ± 0.02^b	1.49 ± 0.26^b	1.34 ± 0.13^c
	Gills	1.69 ± 0.22^a	1.56 ± 0.03^a	1.52 ± 0.01^a	1.42 ± 0.03^a	1.37 ± 0.04^a
	Kidney	2.14 ± 0.10^a	1.83 ± 0.20^a	1.64 ± 0.30^a	1.32 ± 0.10^a	1.26 ± 0.50^b

^a; not significant ($p \leq 0.05$), ^b significant ($p \leq 0.05$), ^c highly significant ($p \leq 0.01$)

GSH activity in *C. gariepinus* serum was unaffected by reduced SDS concentrations ($p > 0.05$), and the changes were consistent with the control. At higher SDS concentrations of 0.15mg/L and 0.20mg/L, enzyme activity was extremely significant ($p < 0.05$, $p < 0.01$) and was dosage and concentration-dependent

compared to the control level. 2.13–2.132 nmol/mL at 0.15mg/L of the toxicant. On days 2,16 and 30, while in the treated fish, it ranges between 1.37 to 1.08 nmol/mL. A similar trend was observed at 0.20mg/L SDS; 1.12 to 1.00 nmol/mL (Figure 1)

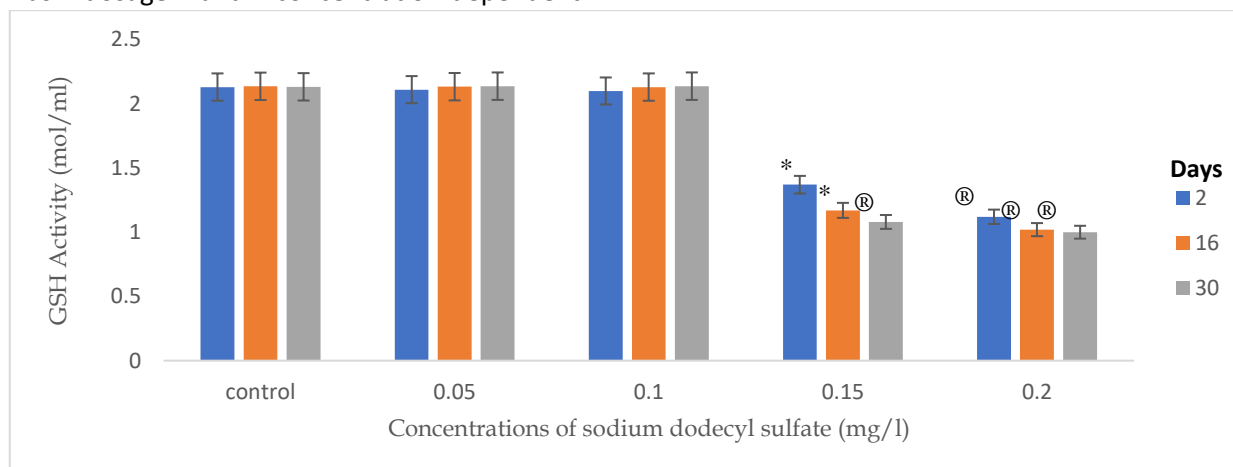


Figure 1: GSH activities in the serum of *C. gariepinus* exposed to sublethal concentrations of sodium dodecyl sulfate; A symbol above the bars indicates significant * ($p < 0.05$); ® ($p < 0.01$) difference between the control and various exposures

Figure 2 depicts the lipase peroxidase response of *C. gariepinus* tissue to SDS. The enzyme activities of untreated fish were comparable to those of fish exposed to the toxicant at concentrations of 2.50mg/L and 5.00mg/L. Although there was no significant ($p > 0.05$) difference between the treated and untreated fish, the treated fish were marginally higher.

The liver showed an evident increase at 10mg/L SDS on days 2 and 10, but it was only significant ($p < 0.05$) on

day 10. No significant ($p > 0.05$) induction was observed in the gills across all regimens. Significant ($p < 0.05$, $p < 0.01$) enzyme induction was observed in the kidney at 7.5mg/L on day 30 and 10mg/L on days 2 and 30 ($p < 0.05$, $p < 0.01$) (Figure 2).

On day 2, the gills saw an induction of 0.210 micromoles/100 g of wet tissue at 2.5 mg/L of SDS, while the kidney saw an induction of 1.178 micromoles/100 g of wet tissue at 10 mg/L of SDS.

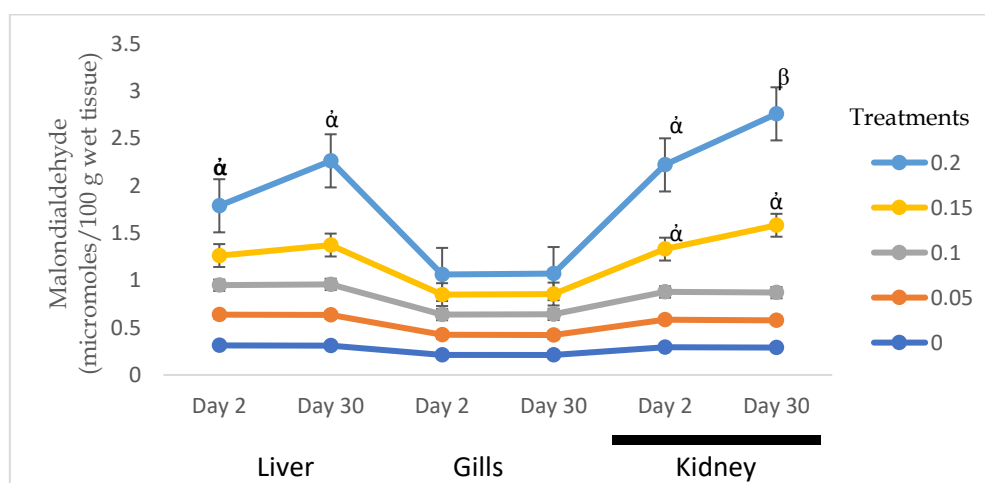


Figure 2: Changes in lipase peroxidase in the tissues of *C. gariepinus* exposed to sublethal concentrations of sodium dodecyl sulfate (mg/L); Data presented as mean \pm SE. A symbol above bars indicates significant differences between the control and the experimental groups α ($p < 0.05$); β ($p < 0.01$)

3.1 Histopathological Examination of the Liver

3.1.1 Control Samples

The livers of the control fish showed no histological abnormalities. The hepatic parenchyma in Figure 3A reveals that the hepatocytes are equally distributed around the blood vessels.

3.1.2 Treatments

The liver of *C. gariepinus* treated with different sodium dodecyl sulphate field concentrations showed several histological alterations compared to the control fish, and the severity of these changes depended on the duration and dosage. On day 2 after exposure to the

surfactant at a concentration of 2.50 mg/l of SDS, the hepatocytes displayed partial discolouration as well as deformed sinusoids Figure 3B.

During the same period of exposure, and an increase in toxicant concentrations to 5.0 mg/l of SDS (Figure 3C), there was partial hepatocyte degeneration and noticeable dark patches; at concentrations of 7.50 mg/l, the fish's liver displayed severe disintegration and infiltration of the hepatocytes (Figure 3D). At 10.0mg/l within the exposure periods, the liver was severely damaged, with hepatocytes exhibiting extensive desquamation and nuclear loss (Figure 3E)

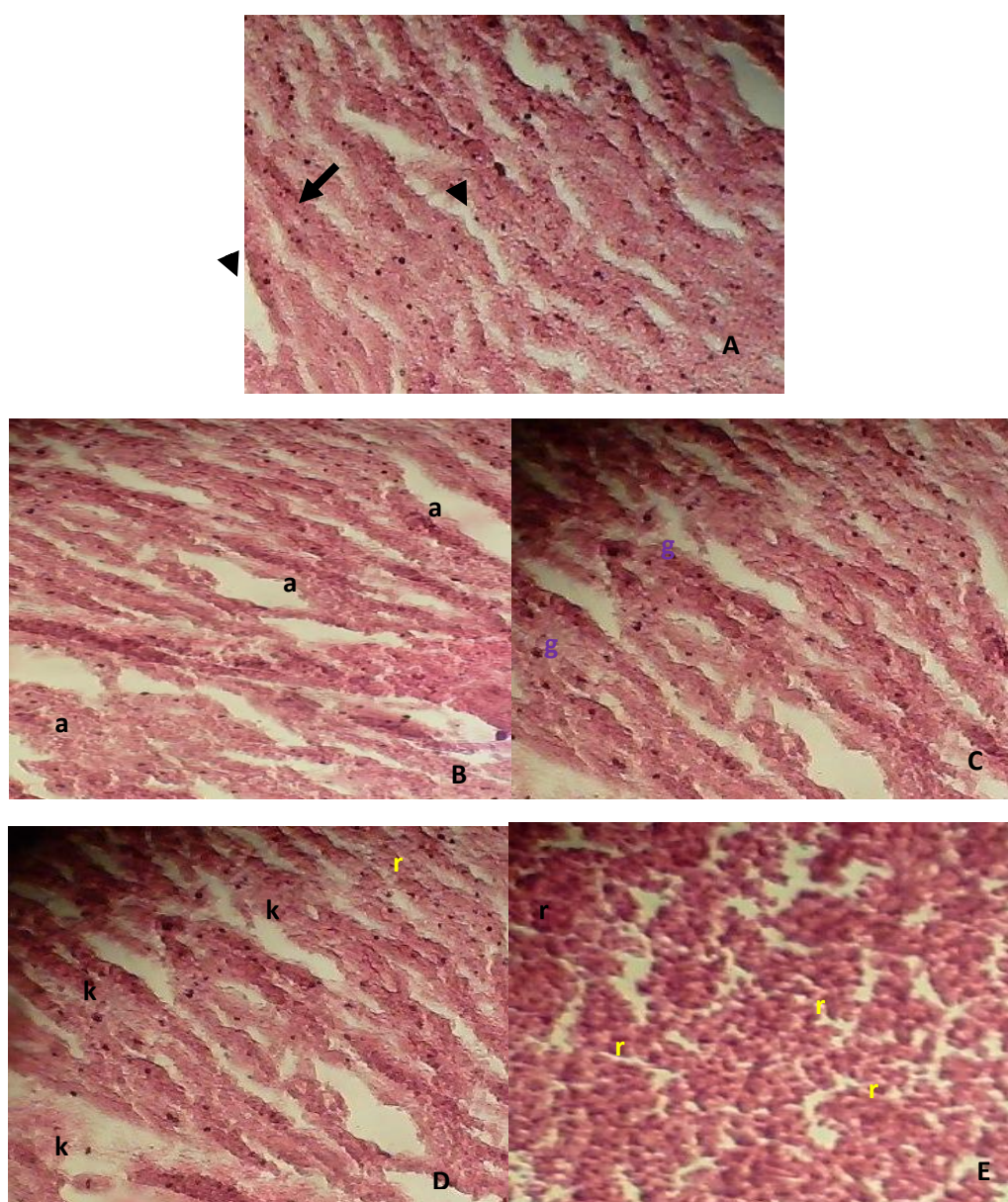


Figure 3: Photomicrograph on day 2; Liver of the control fish, showing normal photomicrograph of the hepatic lobule. The hepatocytes with normal nuclei (arrowhead) and the hepatic sinusoids in between the

hepatocytes (arrow with tail); B: The liver of the fish induced with 2.50mg/l of SDS showing a partial discolouration of the hepatocytes, and distorted sinusoid (a); C: with 5.0mg/l of SDS, there was partial

degeneration of the hepatocytes (g), and conspicuous dark patches; D: 7.50mg/l of the SDS, severe disintegration and infiltration of the hepatocytes (k) and E: 10.0mg/l revealed severe desquamation and loss of nuclei in the hepatocytes (r). (H & E stain x300)

Fish treated on day 30 with the same concentrations as on day 2 revealed distinct and more severe reactions in the liver. Figure 4B1 shows that at 2.50mg/l, there was

significant vacuolar degeneration, dilatation, and congestion in the sinusoid. The liver of the fish displayed severe cholangitis and hepatocyte degeneration when the dose was raised to 5.0 mg/L (Figure 4C1). Hepatocyte necrosis and perivascular inflammatory infiltration can be seen in the fish liver at 7.50mg/L SDS (Figure 4D1), and at 10.0mg/L SDA (Figure 4E1), delimiting the cords of hepatocytes and huge well-demarcated fatty vacuoles may be seen.

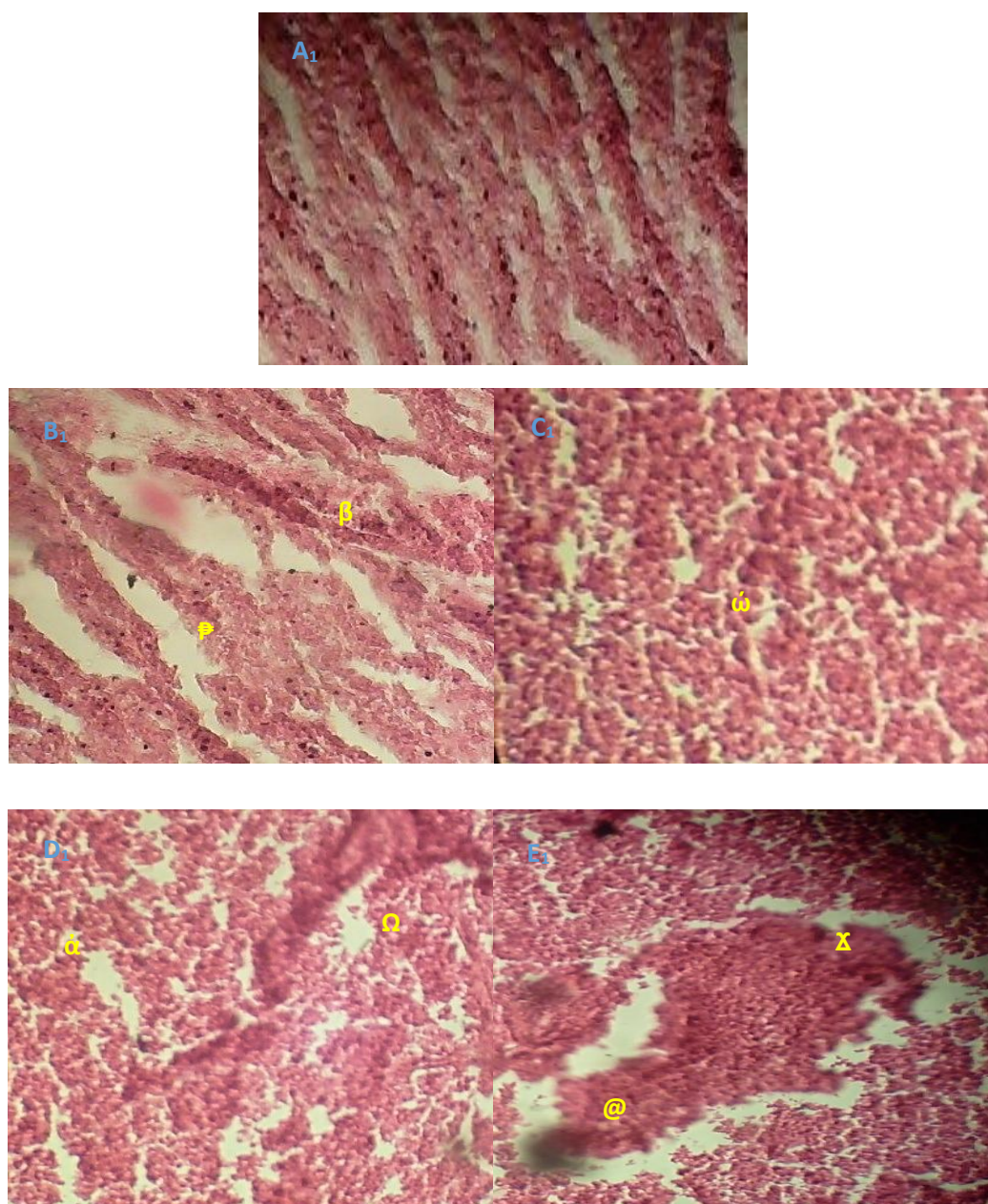


Figure 4: photomicrograph on day 30; A1; Control fish's liver showing normal hepatic lobule, and the hepatocytes with normal nuclei and the hepatic sinusoids in between the hepatocytes; B1: The liver of the fish induced with 2.50mg/l of SDS showed vacuolar degeneration (β), dilatation, and congestion of sinusoid (ϑ); C1: with 5.0mg/l of SDS, there were intensive cholangitis and hepatocyte degeneration (ω); D1:

7.50mg/l of the SDS, hepatocyte necrosis (α) and perivascular inflammatory infiltrate (Ω), and E1: 10.0mg/l revealed delimiting the cords of hepatocytes (@), and large well-demarcated fatty vacuole (X). (H & E stain x300)

4. Discussion

Besides playing a role in DNA and protein synthesis, GSH also scavenges reactive oxygen species (ROS). It was previously believed that maintaining adequate quantities of enzymes' reduced forms of thiol groups (-SH) was GSH's primary role [32, 33]. A dose- and time-dependent reduction in GSH activity was seen in this investigation after exposure to SDS. Organophosphate methyl parathion was shown by Monteiro et al. [33] to reduce glutathione (GSH) and glutathione peroxidase (GTPase) in all *Byrron cephalus* tissues.

Similarly, rainbow trout treated with CPF showed very minor reductions in the effects of OP oxidative stress, supporting the findings of the current investigation. OP pesticides, like those used in our study, decrease antioxidant enzymes [34,35], leading to free radical production and oxidative stress. Low GSH levels have been linked to elevated oxidative stress and lipid peroxidation [36]. While GSH decreased in *Prochilodus lineatus* exposed to Roundup® (glyphosate-based herbicide), Modesto and Martinez [37] finding is contrary to our findings

Because peroxidases are enzymes that reduce different types of peroxides to the corresponding alcohols, malondialdehyde (MDA) levels have been used as a potent marker for LPOs. Several authors have shown that MDA production rises in the presence of pollutants, supporting our findings [38,39]. Patrick [40] opinion, based on his study of free radicals and antioxidants in lead poisoning etiology and treatment, is also congruent with our findings.

In this investigation, the fish had more MDA in their blood, which may have been accompanied by a lower amount of GSH enzymes. This oxidative attack might cause damage to the fish's liver and kidneys. The established ability of SDS to generate oxidative stress is linked to elevated levels of malondialdehyde (MDA) in the serum of the fish. Our study confirms previous research showing a positive correlation between exposure duration and dose and MDA levels. We can establish a principle here: the toxicity of SDS to aquatic organisms was affected by its dosage, duration of exposure, and the animal's access to and dispersion of the chemical.

Toxic substances can be broken down in the liver, but if there are too many of them, the liver's regulatory mechanisms will be overworked, and the liver's structures might be damaged. Since the liver is the

metabolic centre for the detoxification of toxicants and has a greater capacity for absorbing aquatic residues, it was discovered by [41, 42] that it was disproportionately damaged compared to other fish tissues.

In this study, subacute exposure to sodium dodecyl sulphate caused significant histopathological changes in the liver tissues of *C. gariepinusi*, including hepatocyte discoloration, distorted sinusoid, partial degeneration of the hepatocytes, and conspicuous dark patches; hepatocyte disintegration and infiltration; severe desquamation loss of nuclei, vacuolar degeneration; sinusoidal dilation and congestion. The intensity of these changes varied with both dosage and length of exposure. An inflammatory process that impedes the passage of portal venous blood could be responsible for sinusoid dilation [43, 44]. Necrosis in parenchymal tissues was induced by contaminated water with heavy metals from three different locations of Al-Hassa irrigation, as was found by Vasanthi et al. [45] in the case of *Mugil cephalus* due to heavy metal pollution in Ennore Estuary, and by Abdel-Moneim et al. [46] in *Oreochromis niloticus*.

Individual exposure to a low dose of malathion (0.4 mg/L; 1/20th of 96-h LC50 value) for the different durations (1, 4, 8, 12 days) resulted in vacuolization in cytoplasmic, degeneration, and infiltration of lymphocytes in hepatic tissue, as reported here and by Bharti and Rasool [47] in fish *C. punctatus*. Degeneration, vacuolization of hepatocyte cytoplasm, and atrophy of liver cells were observed in *C. punctatus* after 4 days of exposure to 0.8 mg/L of malathion, as reported by Magar and Shaikh [48]. They hypothesized that an imbalance between hepatocytes' rates of synthesis and release may cause vacuolization. Additionally, Tchounwou et al. [49] state that toxicants induce the generation of free radicals that destroy the vital macromolecule constituents of the cells, and so the only reflections of the toxic effect of contaminants are alterations in hepatocytes of organisms.

5. Conclusion

The population at large does not realize that they may be harming local water sources by washing their automobiles. Stormwater is not purified before being dumped into local waterways, unlike sewage water. Streets and driveways are the sources of the filthy water from vehicle washing that ends up in waterways. Even though washing one car may not seem like a big deal, the cumulative effects of car washing create

serious problems for the lakes, creeks, and streams in our area. The sediments and water quality that are impacted by car washing are the aquatic ecosystems. Several pathological changes were observed in *C. gariepinus*, and the results showed that Sodium Dodecyl Sulphate depleted glutathione (GSH), increased malondialdehyde (MDA) activity, and so on. Charitable car washes that are less harmful to the environment by not dumping wash water directly into storm drains but instead into the sanitary system or surrounding landscaping should be revitalized.

Conflict of Interest

I would like to undertake that the research was conducted independently of anyone else and in my lab. The authors confirm that they have no financial or personal stake in the outcome of this article's publication.

Credit author statement ITO

Conceptualization, participating in the writing of the manuscript and running of the data analysis

References

1. Mateo, C., P.M. Knutsen, P.S. Tsai, A.Y. Shih, and D Kleinfeld, 2017. Entrainment of arteriole vasomotor fluctuations by neural activity is a basis of blood-oxygenation-level-dependent“resting-state” connectivity. *Neuron*. 96(4):936 – 948: DOI: [10.1016/j.neuron.2017.10.012](https://doi.org/10.1016/j.neuron.2017.10.012)
2. UNEP. A, 2016. snapshot of the world's water quality: towards a global assessment. United Nations Environment Programme; Nairobi
3. Paul, M.J.and J.L. Meyer, 2001. Streams in the urban landscape. *Annual Review of Ecology and Systematics*; 32:333–365
4. Pandey, R.K., R.N., Singh, S., Singh, N.N Singh, and V.K Das, 2009. Acute toxicity bioassay of dimethoate on freshwater airbreathing catfish, *Heteropneustes fossilis* (Bloch). *Journal of Environmental Biology*; 30(3), 437–440
5. Hamada, T. and Y.Miyazaki, 2004. Reuse of carwash water with a cellulose acetate ultrafiltration membrane aided by flocculation and activated carbon treatments. *Desalin*; 169(169), 257–267
6. Smith, D.J. and H.Shilley, 2009. Residential car wash water monitoring study. Washington: Public Works Department, Surface Water Management
7. Aikins, S. and D.O. Boakye, 2015. Carwash wastewater characterization and effect on surface water quality: A case study of washing bays sited on oda and daban streams in Kumasi. Ghana. *ARPN Journal of Science and Technology*, 5(4), 190–197
8. Mazumber, D. and S. Mukherjee, 2011. Treatment of automobile service station wastewater by coagulation and activated sludge process. *International Journal of Environmental Science and Development*; 2, 64–69
9. Danha, C., B. Utete and S.B. Rufasha, 2014. The potential impact of wash bay effluent on the water quality of a subtropical river. *Journal of Water Resource and Protection*; 6, 1045–1050
10. Sato, T., S., Qadir, T., M., Yamamoto, S.R Endo, and A. Zahoor, 2013. Global, regional, and country level need for data on wastewater generation, treatment, and use. *Agricultural Water Management*; 130, 1–13.
11. Rai, R., Sharma, S., Gurung, D.B.and Sitaula, B.K., 2018. Raut, N. Assessment of environmental impacts of vehicle wash centers at Olakha, Thimphu Bhutan. *International Research Journal of Environmental Sciences*; 7: 1–10.
12. Diphare, M.J., J., Pilusa, E. Muzenda, and M.I Mollagee, Andrew, 2013. review of waste lubricating grease management. 2nd International Conference on Environment, Agriculture and Food Sciences,; Kuala Lumpur (Malaysia)
13. Enujiugha, V.N.and L.C. Nwanna, 2004. Aquatic oil pollution impact indicators. *Journal of Applied Sciences and Environmental Management*; 8: 71–75
14. Harding, J.S. 2005. Impacts of metals and mining on stream communities. In T. A. Moore, A. Black, J. A. Centeno, J. S. Harding, & D. A. Trumm (Eds.), *Metal contaminants in New Zealand*; 343–357
15. Qu, X., N., Wu, T., Tang, Q., Ca,i and Y.S. Park, 2010. Effects of heavy metals on benthic macroinvertebrate communities in high mountain streams. *Annales De Limnologie - International Journal of Limnology*; 46, 291–302
16. Kundu, S., M.V., Coumar, S., Rajendiran, A., Rao, A.S Rao, 2015. Phosphates from detergents and eutrophication of surface water ecosystem

- in India. Current Science, 2015; 108, 1320–1325
17. Rai, R., S., Sharma, D.B., Gurung and B.K. Sitaula, 2016. Potential impacts of discharging vehicle wash wastewater in rivers: A case study in Thimphu and Paro, Bhutan-a review. Bhutan Journal of Research and Development autumn,; 5: 36–52.
18. Okeyo, D., O.G, Mubita, T.K. Harris, D.E. Sahombu, J.Namundjanga, and S. Mulonga, 2004. Indigenous names of fish and fishing gear in the Cuvelai, Kavango, and Caprivi regions of Namibia Afr J Aquat Sci. ; 29:249-258
19. Olagunju, F.I., I.O Adesiyun, and Ezekiel AA . 2007. Economic Viability of Cat Fish Production in Oyo State, Niger. J. Human Ecol: 21(2): 121-124
20. Okwu, O.J. and S. Acheje, 2011. Socio-Economic Analysis of Fish Farming in Makurdi Local Government Area, Benue State, Nigeria. Eur. J. Social Sc. 23: 4-12.
21. Ibrahim, M.D., I.B. Shaheed, H. Abo, E. Yazeed and H. Korani, 2011. Assessment of the susceptibility of polyculture reared African Catfish and Nile tilapia to *Edwardsiella tarda*. J Am Sci, ; 7:779-786
22. James, M.O., L.D., Stuchal, B.A. Nyagode, 2008. Glucuronidation and sulfonation, *in vitro*, of the major endocrine-active metabolites of methoxychlor in the channel catfish, *Ictalurus punctatus*, and induction following treatment with 3-methylcholanthrene Aquat Toxicol, ; 86: 227-238
23. Zaneti, R.N., R., Etchepare, J. Rubio, 2013. Carwash wastewater treatment and water reuse: A case study. Water Sci Technol; 67(1): 82-88.
24. Shabbazi, R., R. Kasra-kemashahi, S. Gharavi, Z. Moosavi-Nejad and F. Borzooee, 2013. Screening of SDS-degrading bacteria from carwash wastewater and study of the alkylsulfatase enzyme activity. Iran J Microbiol.; 5(2): 153-158.
25. Hosseini, F., N., Amirmozafari, F Malekzadeh and N. Ghaemi, 2007. Biodegradation of Anionic surfactants by isolated bacteria from activated sludge. Int J Environ Sci Technol.; 4(1): 127-132.
26. Schleheck, D., M., Lechner, R., Svihonenberger and S., MarcJ-F, Cook, A.M. 2003. Desulfonation of the disulfodiphenyl ether carboxylates from linear alkyl diphenyletherdisulfonate surfactants. Appl Environ Microbiol.; 69: 938-944.
27. Bakacs, M.E., S.E., Yergeau, and C.C. 2013. Obropta Assessment of carwash runoff treatment using bioretention mesocosms. J Environ Eng.; 139(8):1132-1136.
28. Congleton, J.L. and W.J. LaVoie, 2001. Comparison of blood chemistry values for samples collected from juvenile Chinook salmon by three methods. Journal of Aquatic Animal Health, 13, 1682 [https://doi.org/10.1577/15488667\(2001\)013<0168:COBCVF>2.0.CO;2](https://doi.org/10.1577/15488667(2001)013<0168:COBCVF>2.0.CO;2)
29. Olagoke, O., 2008 Lipid Peroxidation and Antioxidant Defense Enzymes in *Clarias gariepinus* as Useful Biomarkers for Monitoring Exposure to Polycyclic Aromatic Hydrocarbons. MSc Theses, University of Lagos, Lagos, Nigeria.; 70pp
30. Gewaily, M.S. and M.M. Abumandour, 2020. Gross morphological, histological, and scanning electron specifications of the oropharyngeal cavity of the hooded crow (*Corvus cornix pallescens*). Anat. Histol. Embryol.; 52, 72–83.
31. Yurumez, Y., M., Cemek, Y., Yavuz, Y.O. and Birdane, M.E. Buyukokuroglu, 2007. The beneficial effect of N-acetylcysteine against organophosphate toxicity in mice. Biological Pharmaceutical Bulletin, 30 (3), 490-494. <https://doi.org/10.1248/bpb.30.490>
32. Monteiro, D.A., J.A. Almeida and F.T. Rantin, 2006. Oxidative stress biomarkers in the freshwater characid fish, *Brycon cephalus*, exposed to organophosphorus insecticide Folisuper 600 (methyl parathion). Comp Biochem Physiol Part C.; 143(2):141–149.
33. Kovacic, P., 2003. Mechanism of drug and toxic actions of gossypol: Focus on reactive oxygen species and electron transfer. Current Medicinal Chemistry, 10, 2711-2718. <https://doi.org/10.2174/0929867033456369>
34. Birkhoj, M., C., Nellesmann, K., Jarfelt, H. and Jacobsen, H.R., Andersen, 2004. Dalgaard M, Vinggaard AM. The combined antiandrogenic effects of five commonly used pesticides. Toxicology and Applied Pharmacology, 15: 10-20. <https://doi.org/10.1016/j.taap.2004.04.016>

35. Sayeed, I., S. Parvez and S. Pandey, 2003. Oxidative stress biomarkers of exposure to deltamethrin in freshwater fish *Channa punctatus* Bloch. *Ecotoxicol Environ Saf*;56(2):295–301
36. Modesto, K.A. and C.B.R. Martinez, 2014. Effects of Roundup Transorb on fish: hematology, antioxidant defenses, and acetylcholinesterase activity. *Chemosphere* 81, 781–787.
37. Benavides, M., J., Fernandez-Lodeiro, P. Coelho, C. Lodeiroa and M.S. Diniz, 2016. Single and combined effects of aluminum (Al₂O₃) and zinc (ZnO) oxide nanoparticles in a freshwater fish, *Carassius auratus*. *Environmental Science and Pollution Research*.;23 (24): 24578–24591. doi: 10.1007/s11356-016-7915-3. [PubMed] [CrossRef] [Google Scholar]
38. Nadhman, A., M.I. Khan and S. Nazir, 2016. Annihilation of *Leishmania* by daylight responsive ZnO nanoparticles: a temporal relationship of reactive oxygen species-induced lipid and protein oxidation. *International Journal of Nanomedicine*.; 11:2451–2461. doi: 10.2147/IJN.S105195. [PMC free article] [PubMed] [CrossRef] [Google Scholar]
39. Patrick, L., 2006. "Lead toxicity part II: the role of free radical damage and the use of antioxidants in the pathology and treatment of lead toxicity," *AlternativeMedicine Review*,; 11:114– 127
40. Pugazhvendan, S.R., N.J. Narendiran, R.G. Kumaran, S. Kumaran and K.M. Alagappan, 2009. Effect of malathion toxicity in the freshwater fish *Ophiocephalus punctatus*-A histological and histochemical study. *World Journal of Fish and Marine Sciences*.;1(3):218–224.
41. Fahmy, G.H., 2012. Malathion toxicity: effect on some metabolic activities in *Oreochromis niloticus*, the tilapia Fish. *Int. J. Biosci. Biochem. Bioinforma*.;2(1):52–55.
42. Mostakim, G.M., M.M. Zahangir, M.M. Mishu, M.K. Rahman and M.S. Islam, 2015. Alteration of blood parameters and histoarchitecture of liver and kidney of silver barb after chronic exposure to Quinalphos. *J. Toxicol*.; doi: 10.1155/2015/415984.
43. Camargo, M.M. and C.B. Martinez, 2007. Histopathology of gills, kidney and liver of a Neotropical fish caged in an urban stream. *Neotropical Ichthyology*, 5: 327-336. <http://dx.doi.org/10.1590/S1679-62252007000300013>
44. Vasanthi, L.A., P. Revathi, J. Mini and N. Munuswamy, 2013. Integrated use of histological and ultrastructural biomarkers in *Mugil cephalus* for assessing heavy metal pollution in Ennore estuary, Chennai. *Chemosphere*, vol. 91, no. 8, pp. 1156-1164. <http://dx.doi.org/10.1016/j.chemosphere..01.021>. PMID:23415490
45. Abdel-Moneim, A.M., M.A.AL-Kahtani, O.M.and Elmenshawy,2012. Histopathological biomarkers in gills and liver of *Oreochromis niloticus* from polluted wetland environments, Saudi Arabia. *Chemosphere*, 88 (8):1028-1035. <http://dx.doi.org/10.1016/j.chemosphere.2012.04.001>. PMID:22546634
46. Bharti, S. and F. Rasool, 2021. Analysis of the biochemical and histopathological impact of a mild dose of commercial malathion on *Channa punctatus* (Bloch) fish. *Toxicol Rep*. Feb 25; 8:443-455. doi: 10.1016/j.toxrep.2021.02.018. PMID: 33717997; PMCID: PMC7933801.
47. R.S. Magar and A. Shaikh, 2013. Effect of malathion toxicity on detoxifying organ of fresh water fish *Channa punctatus*. *Trend in fisheries research: An International Peer Rev. J*.;3(3):723–728.
48. Tchounwou, P.B., A.K. Patlolla, C.G.Yedjou, P.D. Moore and L .Marcelo, 2015. *Sonia Soloneski, Intech Open; Environmental Exposure and Health Effects Associated with Malathion Toxicity, Toxicity and Hazard of Agrochemicals*